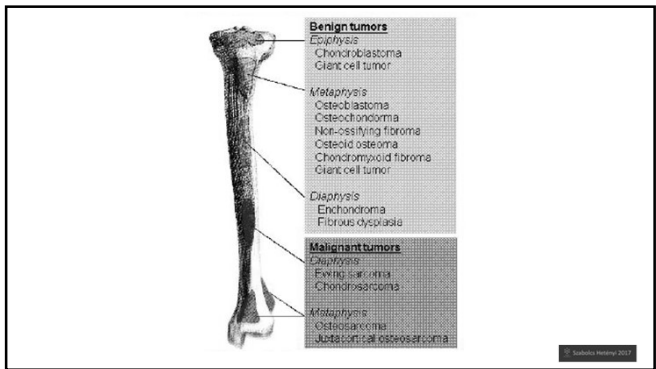
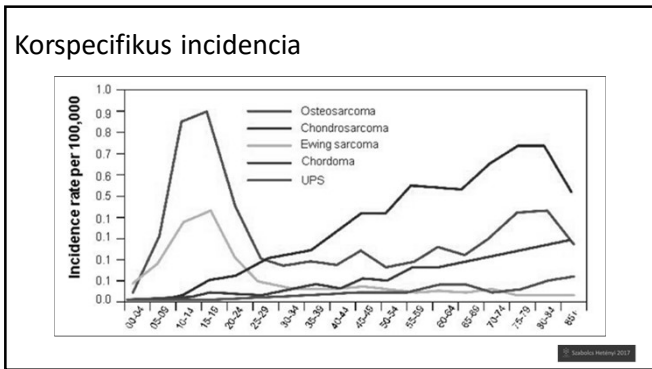
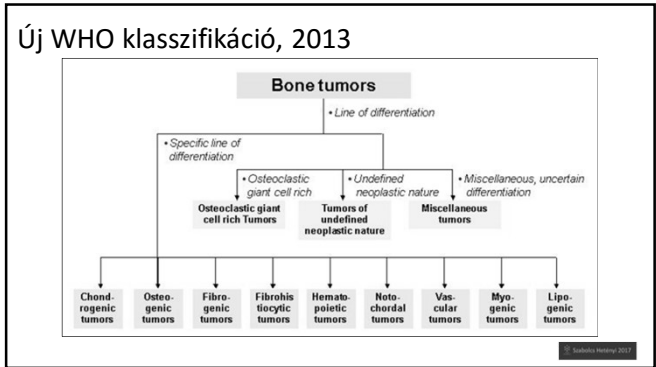



MSK tumorok WHO beosztása 2013

Mozgásszervi Radiológia Tanfolyam
Debrecen, 2017 szeptember 22.

Hetényi Szabolcs
Telemedicine Clinic, Barcelona



Újdonságok

- Új beosztás a tumorok biológiai potenciálja szerint
 - Benignus
 - Intermedier I. (localisan agresszív)
 - Intermedier II. (ritkán metastatizál)
 - Malignus

© Szabó Péter, 2017

Újdonságok

- Malignus fibrozus-hystiocytomát-kivonták
- Néhány új entitást is bevezettek
 - Osteochondromyxoma
 - Atipusos porcos csontumor/chondrosarcoma grade I
 - A kis csontok óriássejtes tumora
 - Benignus notochondrális tumor
 - nem differenciált magas grádusú pleiomorf sarcoma

© Szabó Péter, 2017

Benignus

- Korlátozott számban képes localis recidivára
- Nem destruáló
- Sebészileg teljes kimetszés esetén véglegesen eltávolítható

© Szabó Péter, 2017

Intermedier I. (lokálisan agresszív)

- Gyakran képez localis recidivát
- Infiltratív, localisan destructív
- Metastasisit nem ad
- Sebészileg teljes kimetszés, valamint az környező ép szövetből történő kimetszés esetén véglegesen eltávolítható
- Grade I chondrosarcoma
- osteoblastoma

© Szabó Péter, 2017

Intermedier II. (ritkán metastatizáló)

- Gyakran képez localis recidivát
- Ritkán ad távoli metastasisit <2%
 - Általában tüdőbe
- Chondroblastoma
- Csont óriássejtes tumora

© Szabó Péter, 2017

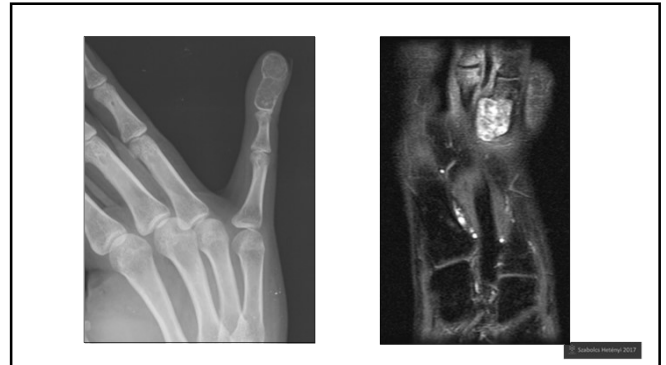Malignus

- Lokálisan destruáló, recidiváló
- Távoli metastasisit ad 20%-100%
- Chondrosarcoma
- Periostealis osteosarcoma

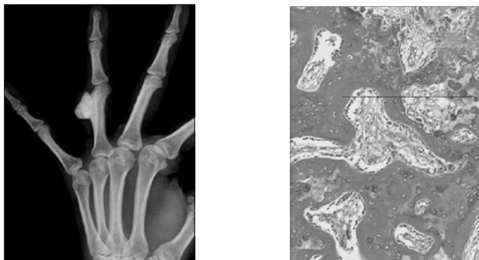
© Szabó Péter, 2017

Chondrogén tumorok

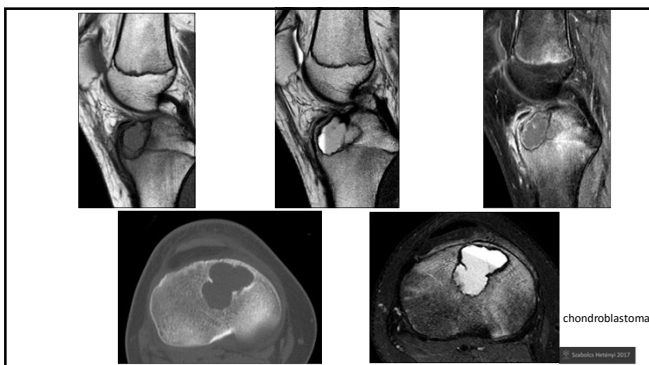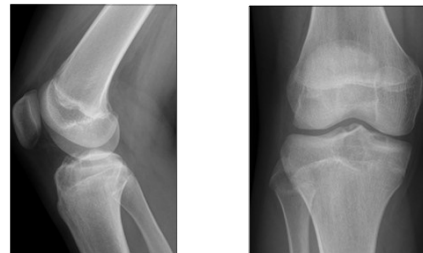Benign	Intermediate (locally aggressive)	Intermediate (rarely metastasizing)	Malignant
<ul style="list-style-type: none"> Osteochondroma Chondroma Enchondroma Periosteal chondroma Osteochondromyxoma Subungual exostosis Bizarre periosteal osteochondromatous proliferation Synovial chondromatosis 	<ul style="list-style-type: none"> Chondromyxoid fibroma Atypical cartilaginous tumor/chondrosarcoma grade I 	<ul style="list-style-type: none"> Chondroblastoma 	<ul style="list-style-type: none"> Chondrosarcoma Grade II Grade III Dedifferentiated chondrosarcoma Mesenchymal chondrosarcoma Clear cell chondrosarcoma



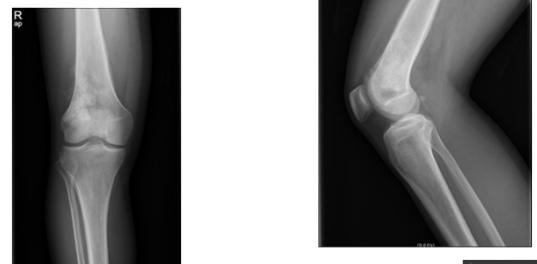
Bizarr parosteális osteochondromatózus proliferáció (Nora-lézió)

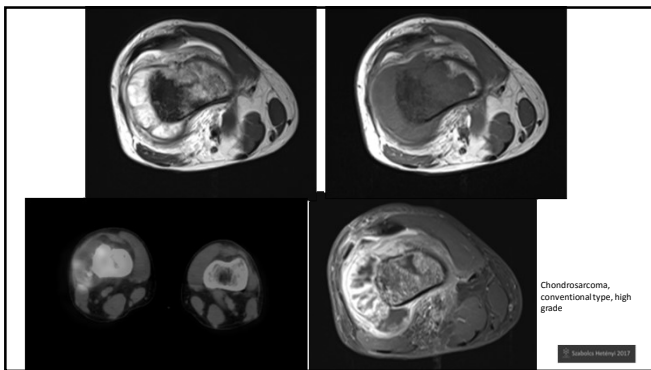
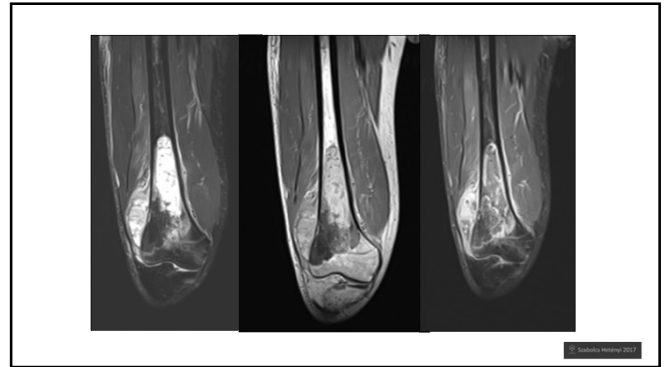
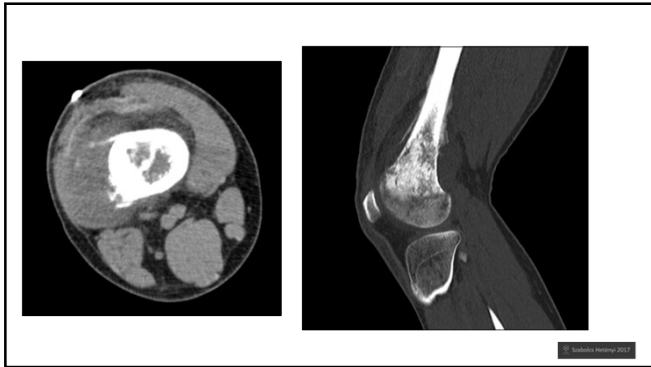


15 éves ffi, tompa térd fájdalom 3 éve, erősödött 3 hete



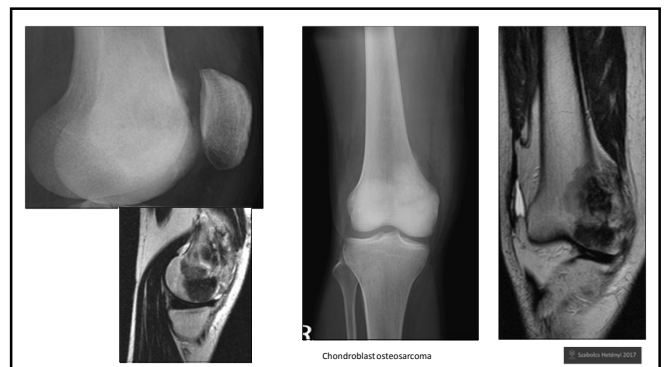
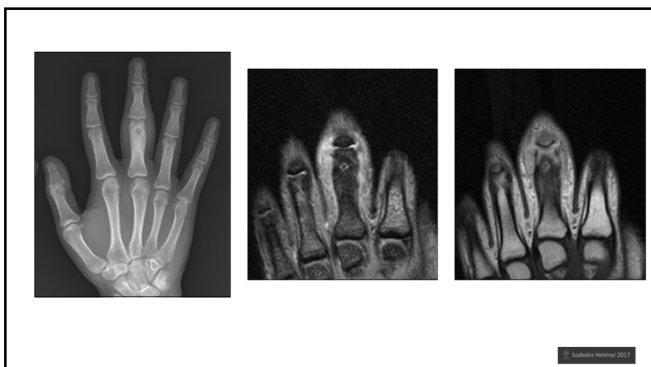22/Ffi
1 hónapos panaszok, fájdalom

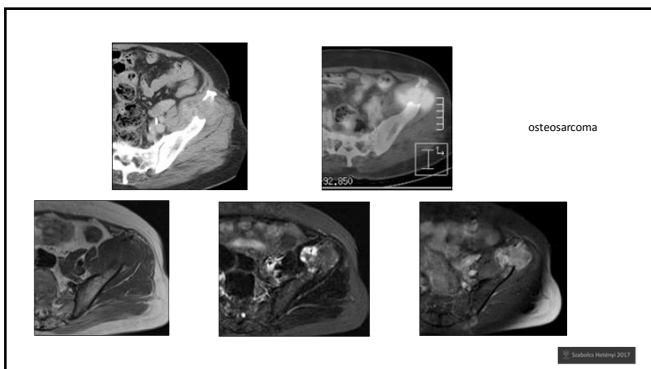
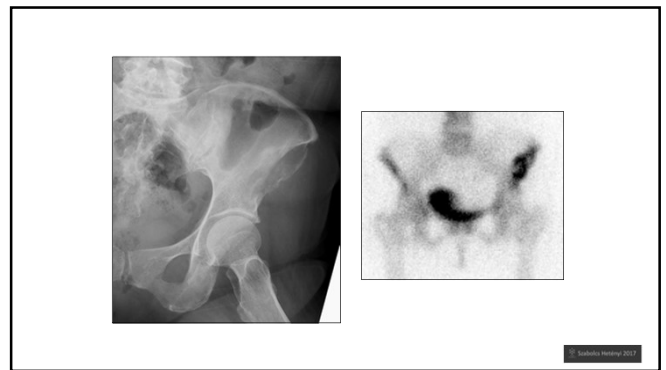
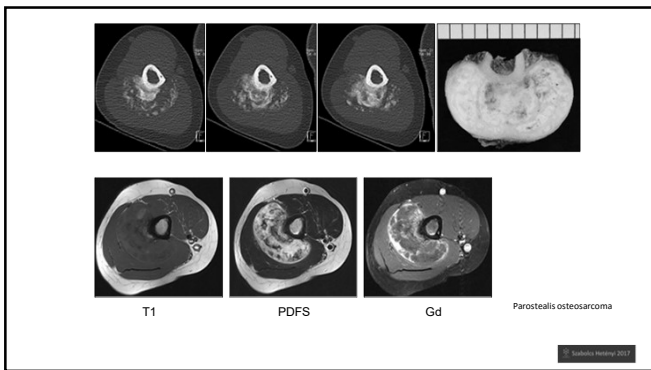
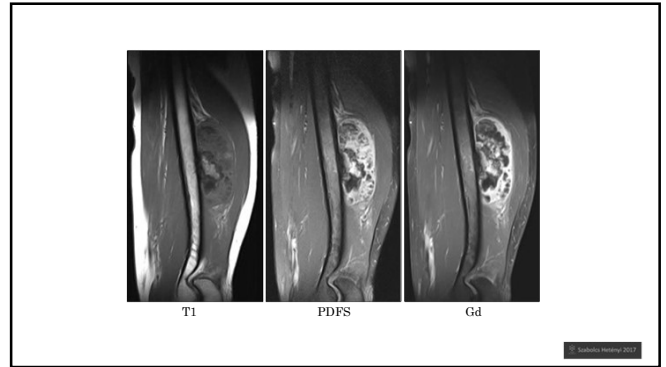
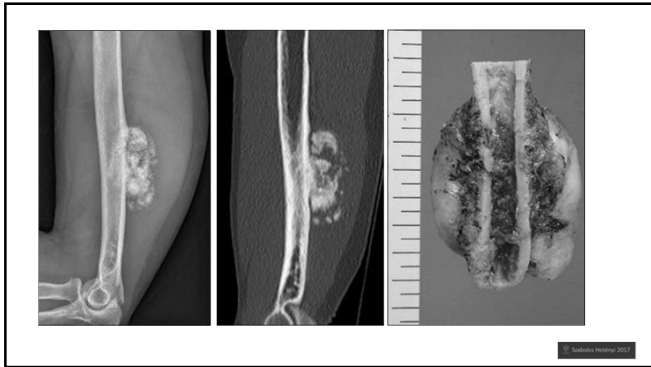




Csontképző tumorok

Benign	Intermediate (locally aggressive)	Malignant
<ul style="list-style-type: none"> Osteoma Osteoid osteoma 	<ul style="list-style-type: none"> Osteoblastoma 	<ul style="list-style-type: none"> Low-grade osteosarcoma Conventional osteosarcoma Chondroblastic osteosarcoma Fibroblastic osteosarcoma Osteoblastic osteosarcoma Telangiectatic osteosarcoma Small cell osteosarcoma Secondary osteosarcoma Parosteal osteosarcoma Periosteal osteosarcoma High-grade surface osteosarcoma

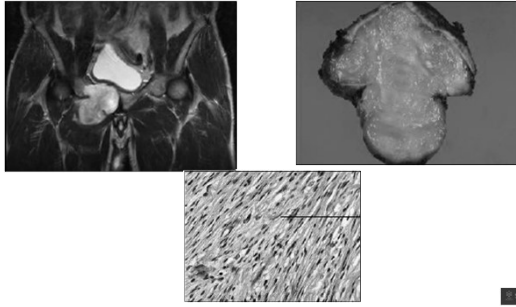




Fibrogén tumorok

Intermediate (locally aggressive)	Malignant
• Desmoplastic fibroma of bone	• Fibrosarcoma of bone

Fibrosarcoma

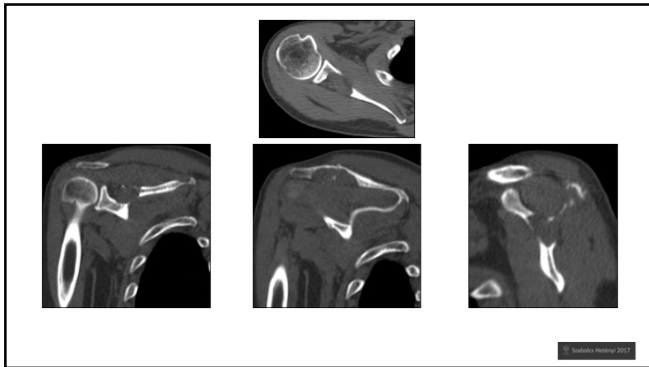


© Székely István, 2017

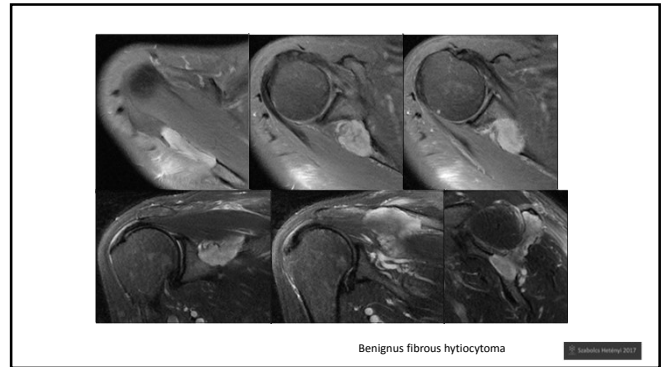
Fibrohistiocytosis tumorok

Intermediate (locally aggressive)	Malignant
<ul style="list-style-type: none"> • Benign fibrous histiocytoma/ non-ossifying fibroma 	

© Székely István, 2017



© Székely István, 2017



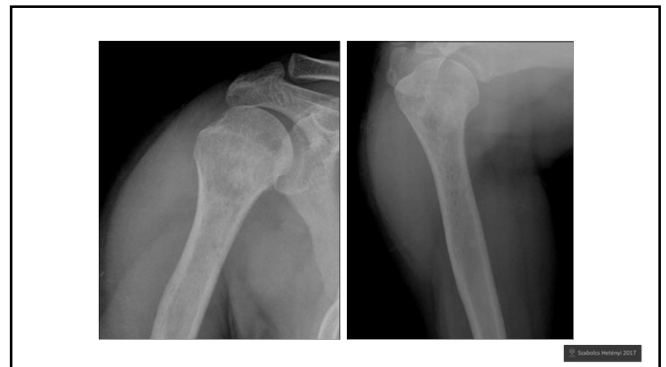
Benignus fibrous histiocytoma

© Székely István, 2017

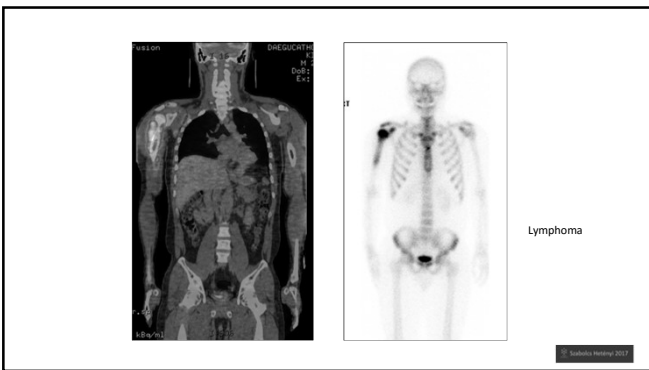
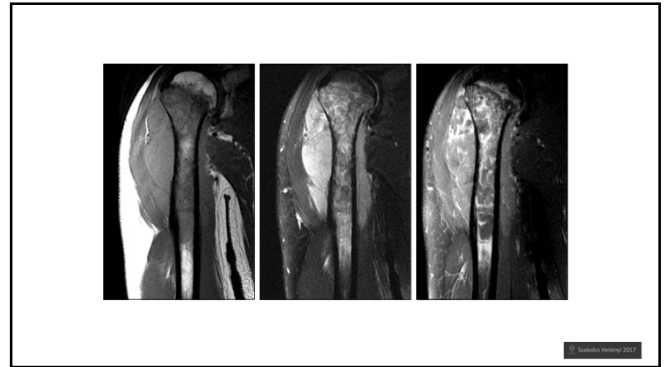
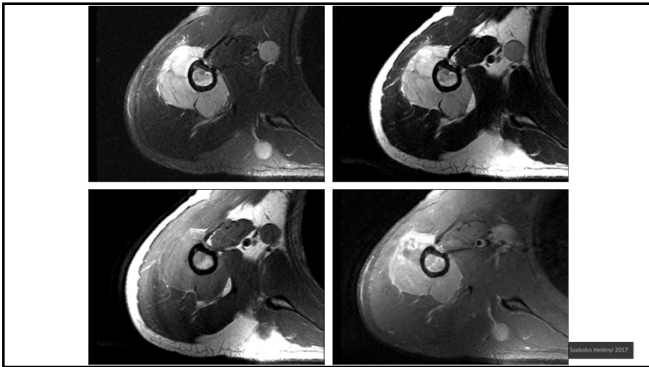
Vérképző eredetű csonttumorok

Malignant
<ul style="list-style-type: none"> • Plasma cell myeloma • Solitary plasmacytoma of bone • Primary non-Hodgkin lymphoma of bone

© Székely István, 2017

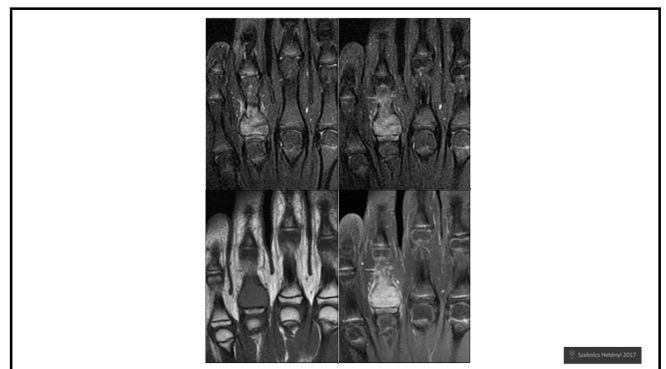
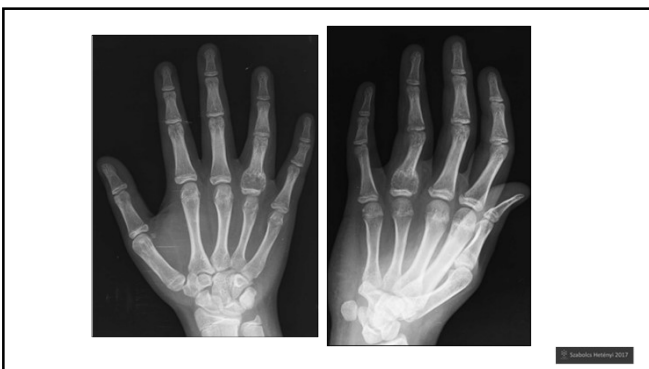

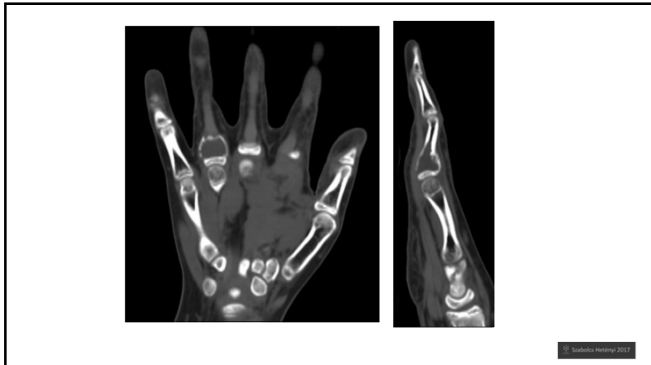
© Székely István, 2017



Osteoclast, óriássejtes tumorok

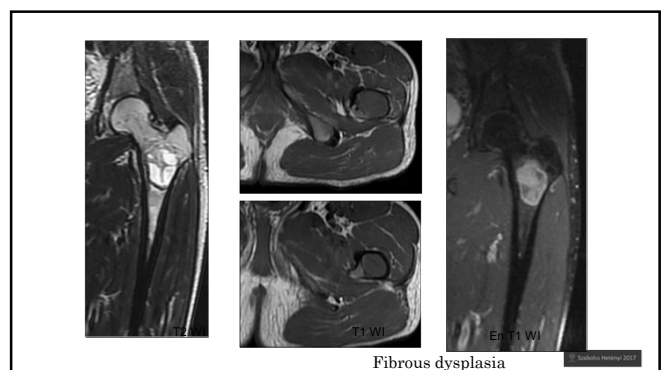
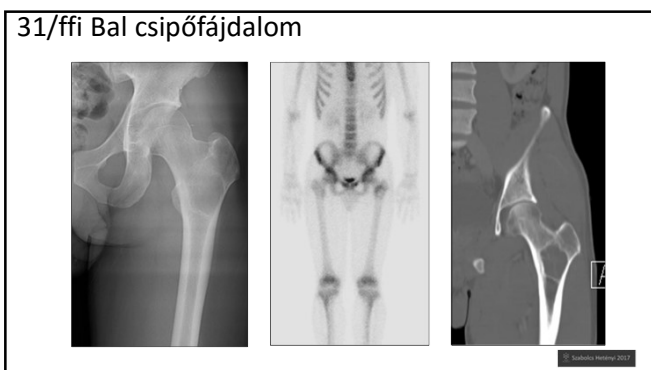
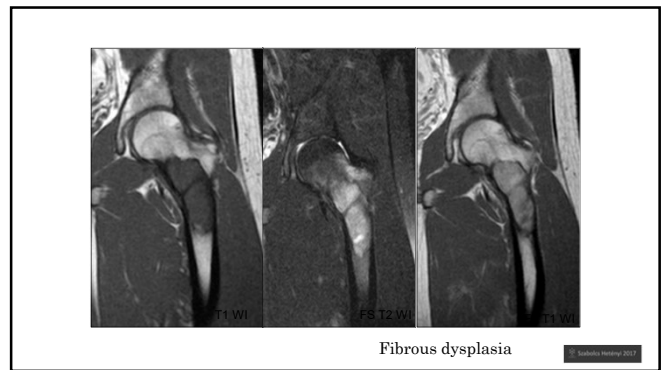
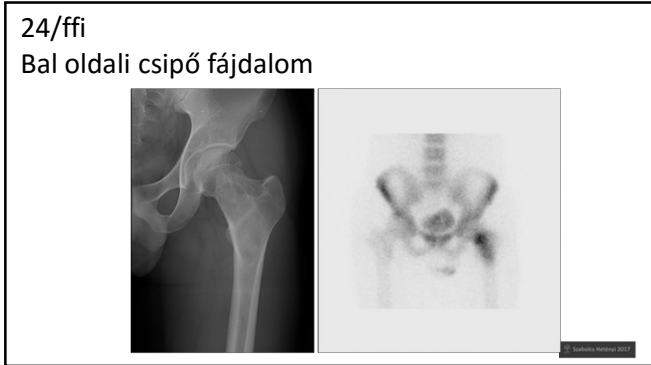
Benign	Intermediate (locally aggressive, rarely metastasizing)	Malignant
• Giant cell lesion of the small bones	• Giant cell tumor of bone	• Malignancy in giant cell tumor of bone

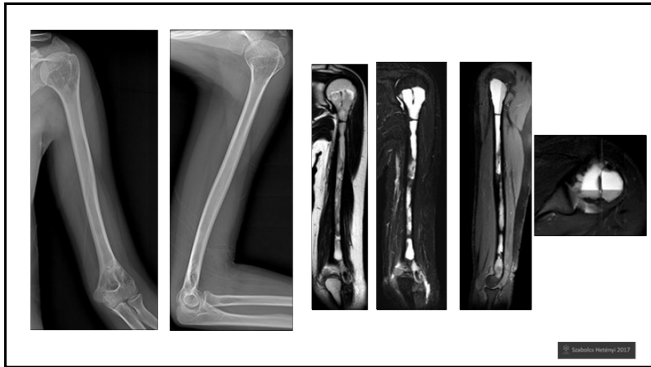




Egyéb

Benign	Intermediate (locally aggressive)
<ul style="list-style-type: none"> • Simple bone cyst • Fibrous dysplasia • Osteofibrous dysplasia • Chondromesenchymal hamartoma • Rosai-Dorfman disease 	<ul style="list-style-type: none"> • Aneurysmal bone cyst • Langerhans cell histiocytosis • Monophasic Polyphasic • Erlenmeyer-Chester disease





Köszönöm a figyelmet

